



## A conservative approach for deep dermal burn wounds using polarised-light therapy

S. Monstrey, H. Hoeksema, H. Saelens, K. Depuydt, M. Hamdi, K. Van Landuyt and P. Blondeel

*Department of Plastic Surgery, University Hospital Gent, Belgium*

**SUMMARY.** This article reports a clinical study investigating the role of polarised-light therapy in the conservative treatment of deep dermal burn wounds. In 22 out of 67 patients with deep dermal burn wounds, clinical evaluation revealed only a very limited potential for spontaneous healing, and, despite the fact that the majority of the surgeons (four out of six) would have recommended surgery, these patients were treated conservatively with polarised-light therapy (400–2000 nm, 40 mW cm<sup>-2</sup>, 2.4 J cm<sup>-2</sup>) until complete closure. Evaluation by a panel of four surgeons, all experts in burn surgery, revealed that conservative treatment of these deep dermal wounds with polarised-light irradiation resulted in a significantly shorter healing time, with almost no hypertrophic scarring, and optimal aesthetic and functional results at long-term follow-up. No extension of the hospital stay was required. Polarised-light therapy may be a valuable way of avoiding surgery in patients with deep dermal burns. © 2002 The British Association of Plastic Surgeons

**Keywords:** deep dermal wounds, polarised-light therapy, spontaneous healing, hypertrophic scarring.

Some recent literature reports have suggested that treatment with low-energy lasers and polarised light may accelerate wound healing. However, other investigators have published diverging results, and the benefits of phototherapy in wound healing are still controversial. This lack of consensus led us to investigate the role of phototherapy further, in a clinical study on deep dermal wounds, whose treatment is still controversial. Indeed, even experienced surgeons often find it impossible to predict whether a better aesthetic and functional result will be obtained by early excision and skin grafting or whether to recommend a conservative approach that avoids surgical intervention but increases the risk of hypertrophic scarring and contractures. Here, we report a clinical study investigating the role of phototherapy in the conservative treatment of deep dermal burn wounds.

Superficial dermal burns are always treated conservatively, and full-thickness burns always require surgery.<sup>1</sup> However, more than 50% of burn wounds are deep second degree or deep dermal burn wounds.<sup>2</sup> The treatment of choice for these 'intermediate thickness' burns is still much debated and controversial.<sup>3,4</sup> The main question is whether better aesthetic and functional results can be obtained by early excision and skin grafting or whether conservative therapy should be recommended. Conservative treatment avoids a surgical intervention, but may result in prolonged wound healing with a high risk of hypertrophic scarring and contractures. It is universally agreed that the faster a second-degree burn wound heals, the less necessary surgery becomes.

Recently, low-power lasers and polarised light have been given considerable attention in wound-healing therapy. Different biological effects have been observed after phototherapy, including the stimulation of cell proliferation (especially in fibroblasts), the release of growth factors and the enhancement of collagen synthesis.<sup>5–13</sup> Several clinical studies have revealed accelerated wound closure, with increased wound epithelialisation and improved tensile strength of scars.<sup>14–19</sup> However, other investigators have found no improvement in wound-healing processes and were not able to reproduce the above-mentioned effects of phototherapy.<sup>10,20–22</sup>

Because of these inconsistent and contradictory results, there still is no consensus on the real effect of phototherapy on wound healing, and many clinicians, especially surgeons, are still very sceptical of this therapy.

In a previously reported prospective randomised single-blind study performed in our institution, 20 pairs of identical donor sites of split-thickness skin grafts were treated according to the same wound-care protocol.<sup>19,23</sup> One site was treated with polarised light and the other was not; each patient served as their own control. The wound-healing process was evaluated on a daily basis in a standardised manner by two independent blinded observers. The results of this study demonstrated that polarised light had a significantly beneficial effect on wound healing, resulting in faster epithelialisation of the wound and an improved quality of early scar-tissue formation.<sup>19,23</sup>

This clinical study in burn patients was set up to investigate whether polarised-light therapy could accelerate wound closure in deep dermal burn wounds, thus reducing the need for surgery, without increasing hypertrophic scarring and contractures.

## Materials and methods

Since 1997, most superficial and deep second degree burns, as well as residual defects after initial grafting procedures, have been treated in our department using polarised-light therapy. A linearly polarised light source (Biopton, Mönchaltorf, Switzerland) with the following technical characteristics was used: wavelength: 400–2000 nm; degree of polarisation: >95%; power density: 40 mW cm<sup>-2</sup>; light energy: 2.4 J cm<sup>-2</sup>. The study was approved by the Ethical Committee of the University Hospital. All wounds were treated according to the same protocol: polarised-light therapy was given for 6 min daily at a distance of 10 cm, and the wound was then dressed with Vaseline gauze in combination with silver sulphadiazine (Flamazine). Standardised colour photographs were taken every day. Phototherapy was stopped when the wound had completely healed. At that time all patients were submitted to the usual standardised protocol of customised pressure garments, if necessary in combination with silicone inlays, especially on concave and irregular surfaces. The patients were usually followed up in the outpatient clinic every 2–6 weeks.

In 1997 and 1998, 67 patients with large areas of deep dermal burns were treated in our burn centre. From this group we selected 22 cases in which the majority (at least four out of six) of surgeons in our burn centre would have recommended surgical treatment with tangential excision and skin grafting. These patients did not undergo surgery for various reasons: the need to operate on other burned areas first; a poor general condition; the patient's wish not to undergo surgery; and, last but not least, the encouraging clinical results and those of the previous prospective single-blind study.

This group of 22 patients consisted of 12 males and 10 females, with a mean age of 38.6 years (range: 1–88 years). The mean total body surface area burned was 14.4% (range: 2%–36%) and the mean area treated with polarised light was 10.2% (range: 2%–30%). The mean hospital stay was 18.1 days (range: 1–53 days). All these deep dermal burns were treated conservatively using polarised light, as described above, until the wounds were completely closed. The mean follow-up was 10.2 months (range: 7–25 months).

Clinical assessment of the burn wounds was performed by a panel of four surgeons, all heads of different burn units and all having more than 15 years experience in burn surgery. They were not informed of the reasons for or the motive behind this evaluation. The four surgeons were asked to evaluate three series of standardised colour slides and to fill out a questionnaire. A first series of 30 colour slides, all showing deep dermal burn wounds, included the 22 study cases together with eight control cases. The complete clinical history of the patient was given, but no details of the therapy. The surgeons were asked whether these burn wounds should be treated surgically and, if treated conservatively, how long healing would take and whether they would expect hypertrophic scarring. A second series of slides was composed of the 22 study cases, with a first picture before treatment, a second picture halfway through wound closure and a third picture at the time of complete epithelialisation. The surgeons were asked to estimate the time interval between

the successive slides and to comment on whether they expected hypertrophic scarring and contractures. In a third series, final long-term follow-up pictures of the 22 cases were shown. The surgeons were asked to score the result as much worse, worse, comparable, better or much better than the result they would have expected after surgical or conventional conservative therapy. The answers were statistically analysed by an independent expert.

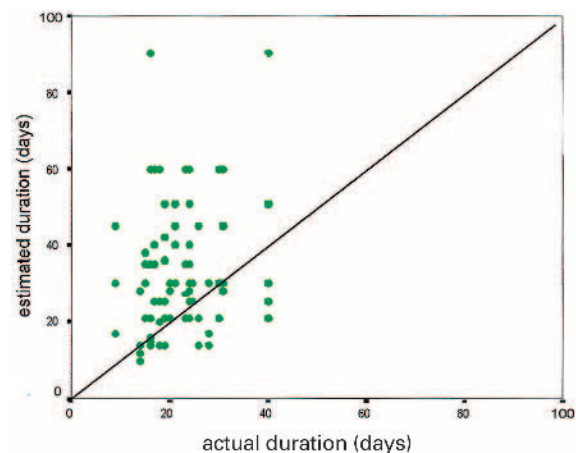
## Results

The panel of surgeons would have operated in 18, 12, 11 and 10 of the 22 cases, respectively (mean 12.8 cases or 59%). In 16 cases (73%) at least two of the experts were convinced that surgery was necessary.

The mean time to wound closure was 3.2 weeks (range: 2.1–5.5 weeks). There was no correlation between the estimated healing period and the actual time to complete wound healing (using the Pearson correlation test). Using the Wilcoxon matched-pairs signed-ranks test, the estimated time for healing was found to be significantly longer ( $P < 0.001$ ) than the actual healing time, with mean values of 41 days and 22 days, respectively (Fig. 1).

The surgeons were very consistent in answering the questions: there was a strong correlation ( $P < 0.001$ , Fisher's exact test) between the indication for surgery and the expectation of hypertrophic scarring after conservative treatment. In fact, we saw hypertrophic scarring in only one patient, who was not compliant in wearing pressure garments. This rate of hypertrophic scarring was significantly lower ( $P < 0.001$ ) than that expected by the observers ( $\chi^2$  test): the expected incidence of hypertrophic scarring in the 22 cases was 13, 17, 16 and 17 cases, respectively, with a mean of 15.8 cases.

The experts rated the clinical results at least comparable with the expected results after surgical treatment in 73.8% of cases ( $P < 0.001$ , Wilcoxon matched-pairs signed-ranks test) (Fig. 2). In the subset of cases that were considered to require surgery, 65.3% scored comparable, better or much better. Compared with a



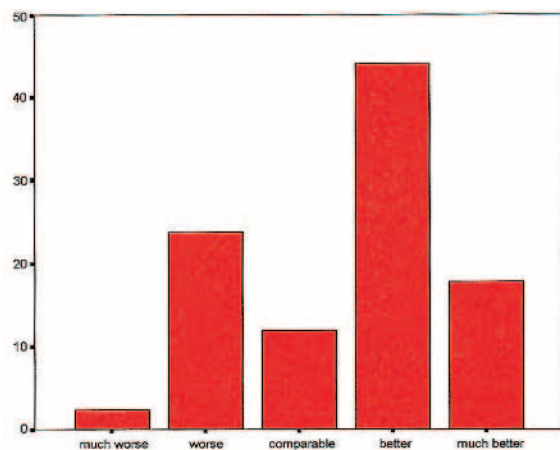
**Figure 1**—Real versus estimated time for wound healing. The estimated time was significantly longer than the actual time (Wilcoxon matched-pairs signed-rank test:  $P < 0.001$ ).

standard conservative treatment, 97.6% of the cases were rated at least comparable. Half of the cases were rated as better or much better.

There was no significant difference between the mean hospital stay in this group of 22 patients and that of a similar patient population treated 3 years previously (mean: 18.1 days versus 19.6 days).

All observers expressed their surprise at the remarkably good function and aspect of the skin in the hand-burn cases. In none of these cases was any loss of function observed during or after phototherapy.

Representative results are shown in Figures 3–7.



**Figure 2**—Evaluation of the results as compared with the expected results after surgery. (Wilcoxon matched-pairs signed-ranks test:  $P < 0.001$ .)

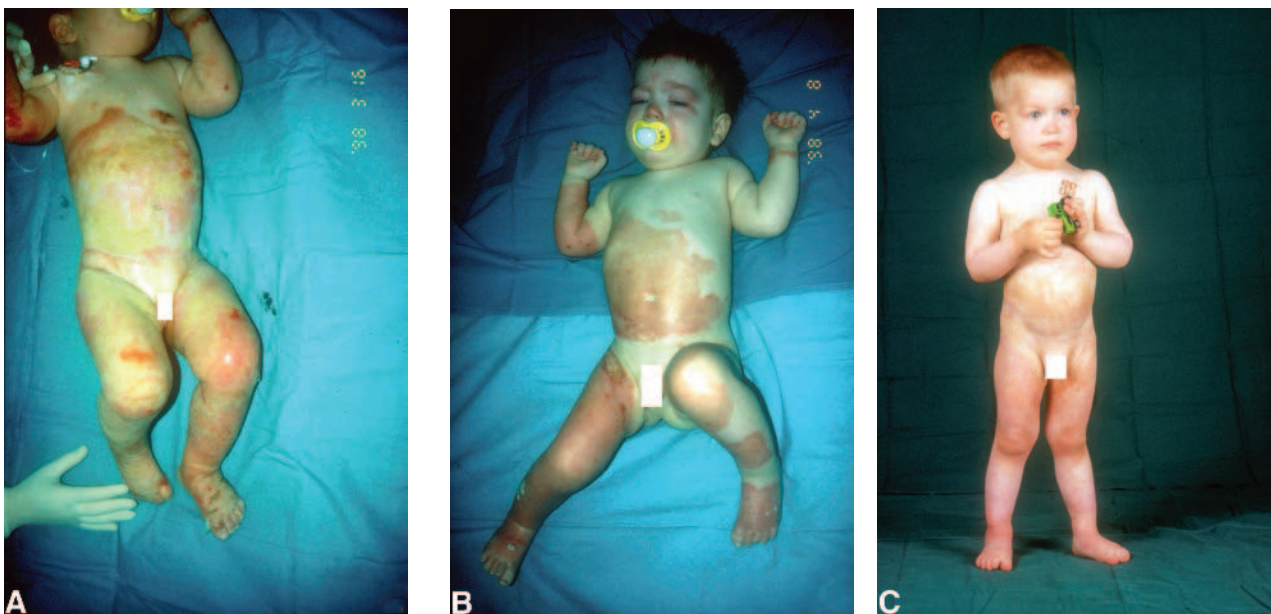
## Discussion

The treatment of deep second degree burns is still very controversial.<sup>1,2</sup> These deep dermal burns often have limited or questionable healing potential, resulting in prolonged granulating wounds. Therefore, the majority of surgeons advocate early excision and skin grafting of these burns to reduce the risk of infection, decrease hypertrophic scarring and contractures, and shorten hospital stay.<sup>3,4</sup> Particularly in cases of deep dermal burns to the hand, most surgeons consider that surgery is required to achieve an optimal functional and aesthetic outcome.<sup>1-4</sup>

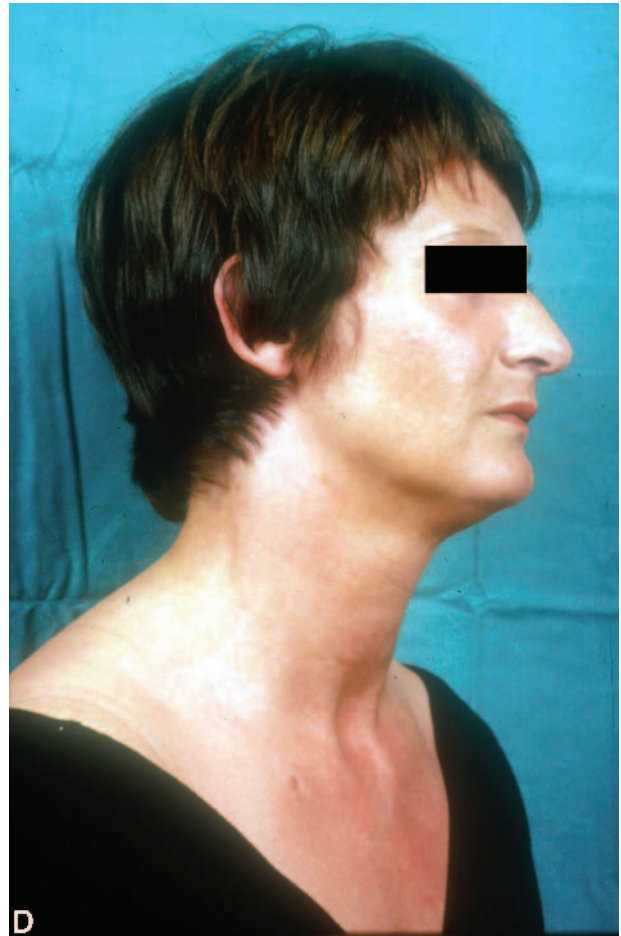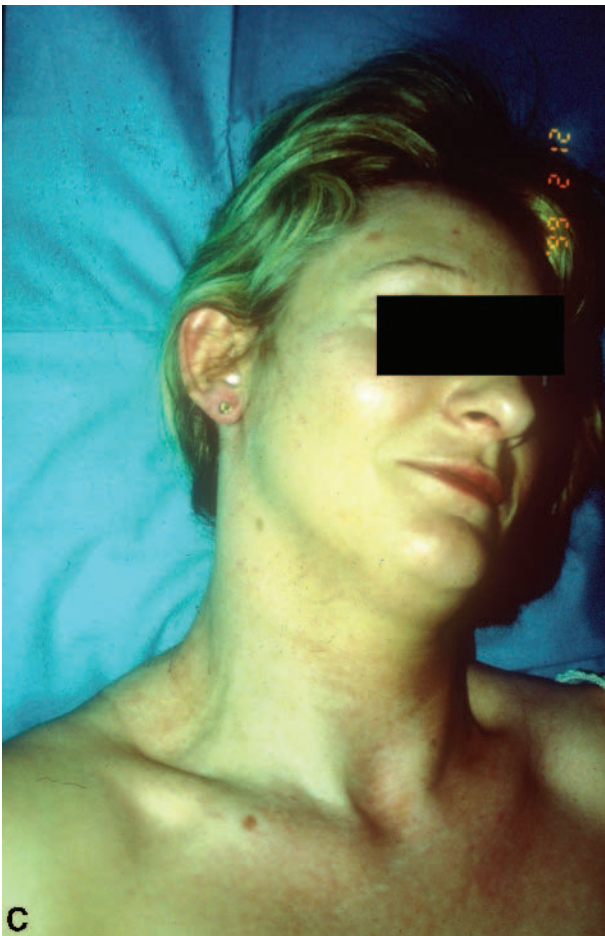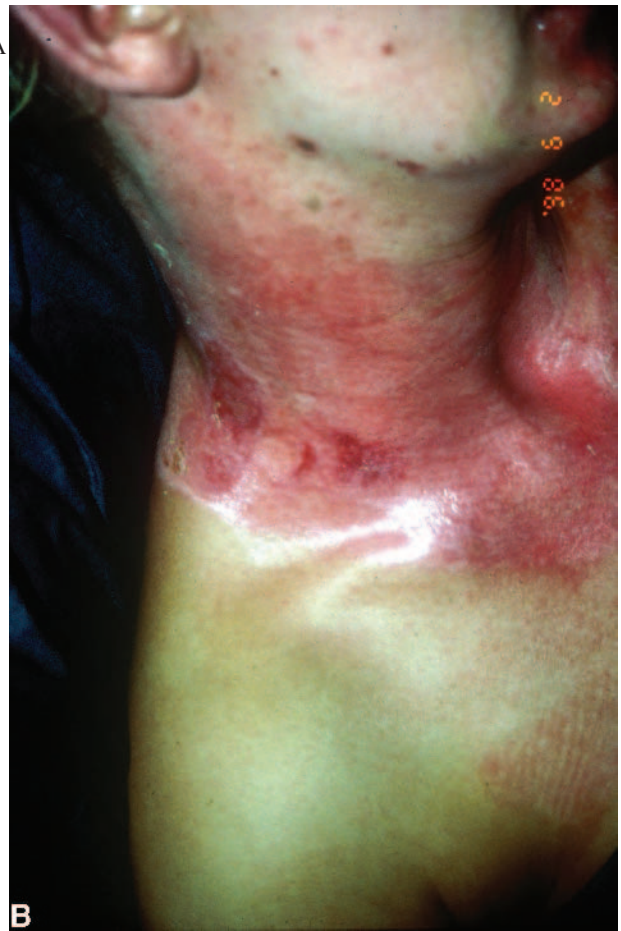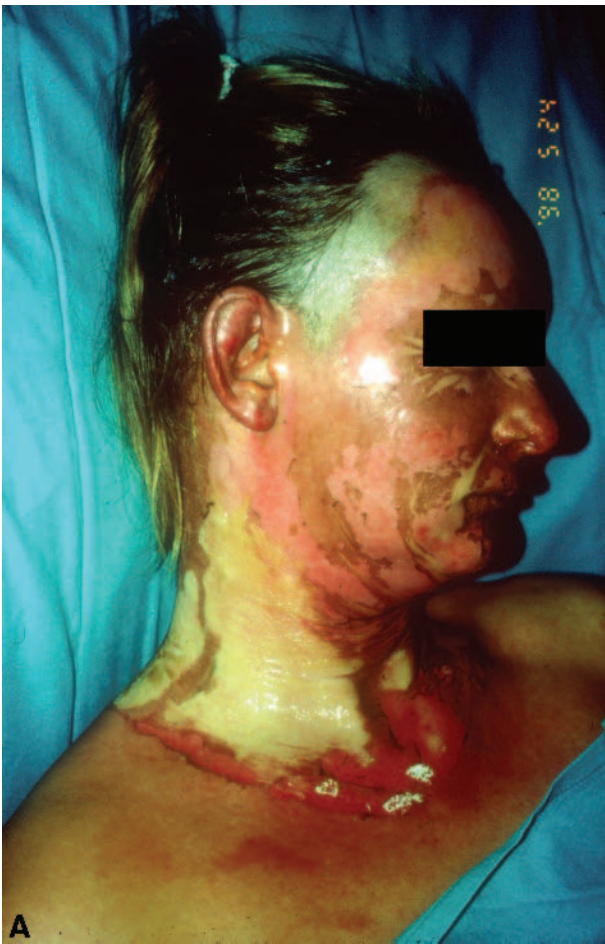It is universally agreed that the faster a second degree burn heals, the less likely it is to require surgery and the less likely it is that hypertrophic scarring and contractures will develop. Many articles have suggested that treatment with low-energy lasers and polarised light might accelerate wound healing. Subsequently, we set up a clinical study in burn patients to investigate whether this therapy might be beneficial in the healing of deep dermal wounds.

Phototherapy has been studied in many areas of medicine over many years.<sup>5-22</sup> Mester et al evaluated the effects of laser irradiation on cells over 30 years ago, and discovered that low-energy laser irradiation has a biostimulating effect.<sup>5</sup> In a later clinical study, they found that laser irradiation stimulated wound healing and resulted in faster closure of the wounds, especially in cases of refractory and persistent ulcers.<sup>6</sup>

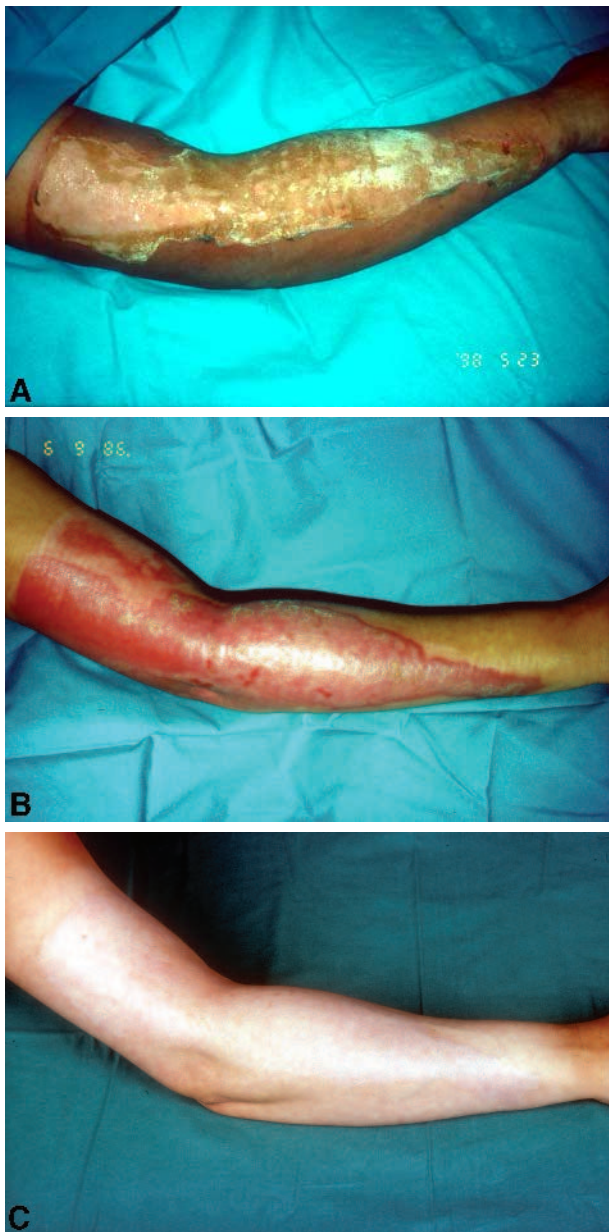Fenyö developed a polarised-light source and observed a similar stimulation of wound healing to that seen with the low-energy laser.<sup>11</sup> Polarised light was found to trigger human cellular and humoral defences.<sup>11-13</sup> Moreover, this light source had several advantages over the laser, including lower costs, fewer risks, a larger treatment area and no important user skills.



**Figure 3**—A 1-year-old boy with burns to the thorax, abdomen, right arm and anterior legs after being scalded by hot oil. (A) Appearance 8 days after the injury. (B) Appearance at 1 month, showing almost complete wound closure. (C) Follow-up after 1 year.



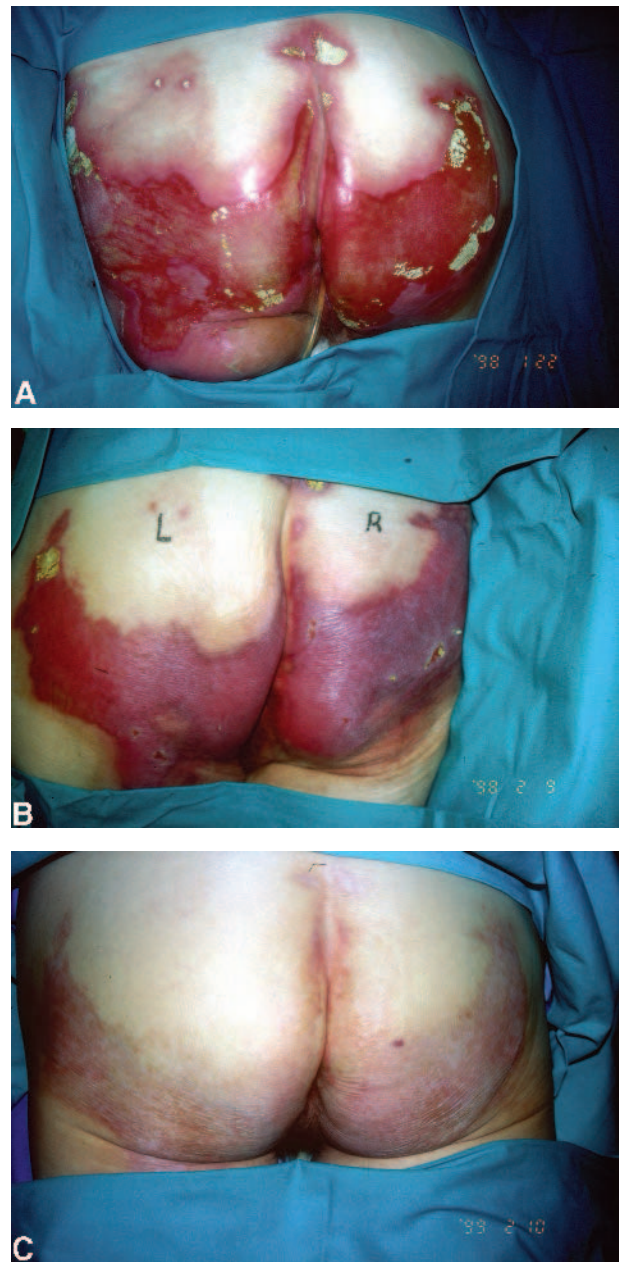
**Figure 4**—A young woman with a flame burn of the face and neck. (A) Appearance 2 days after the injury. (B) The wound was closed after 12 days. (C) Appearance after 8 months. (D) Appearance after 15 months.



**Figure 5**—A young woman with a flame burn of the right arm. (A) Appearance 2 days after the injury. (B) The wound was closed after 19 days. (C) Appearance after 11 months.

Several other authors have reported different biological effects after polarised-light irradiation, including stimulation of cell proliferation (especially in fibroblasts), release of growth factors and enhancement of collagen synthesis.<sup>11,14–16</sup> In accordance with the reordering of liquid-crystal molecules after light irradiation, linearly polarised light is thought to interact with the polar heads of the lipid double layer of the cell membrane, resulting in structural changes that influence the cellular processes connected with the cell membrane.<sup>11,14,15</sup>

The first clinical reports of the use of polarised light in the treatment of wounds were very promising: different investigators observed accelerated wound closure, increased wound epithelialisation and improved tensile strength of scars.<sup>7–9,11,17,18</sup> However, other investigators

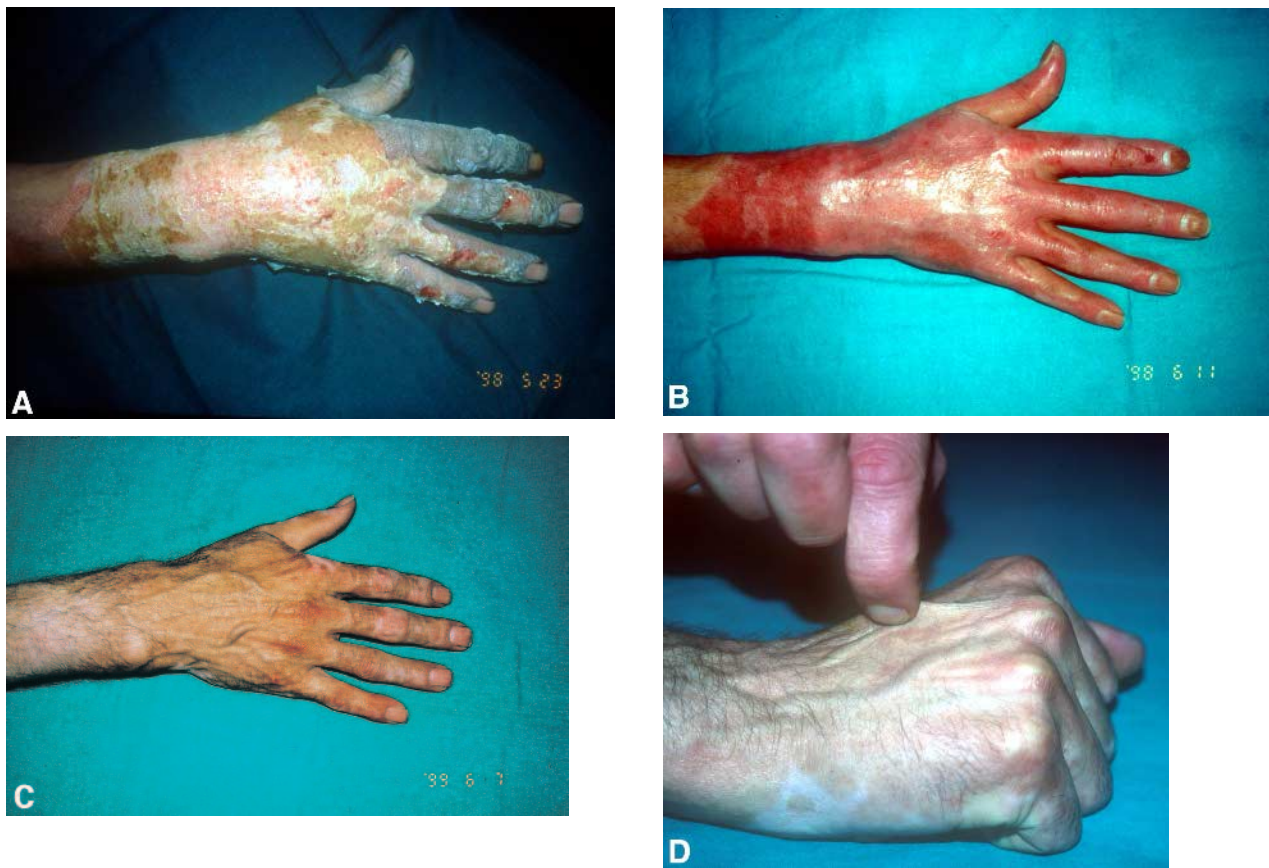

**Figure 6**—Scald burns of the buttocks in an 82-year-old woman. (A) Appearance 10 days after the injury, at the initiation of light therapy. (B) The wound was closed 18 days later. (C) Appearance after 1 year.

were unable to reproduce these effects and found no improvement in the wound-healing process after irradiation with low-power lasers or polarised light.<sup>10,20–22</sup>

As a result of these inconsistent and conflicting data, there is still no consensus on the real effect of phototherapy in the healing of wounds in general, and very little is known about its possible role in the healing of burn wounds.

In order to establish the indications for using polarised-light therapy in burns, we first used this treatment in a pilot study of 15 patients with difficult wounds, such as deep dermal burns, residual defects after grafting procedures using widely meshed skin grafts, and non-healing donor sites. Despite being highly sceptical of the therapy, we were impressed by the apparently beneficial effects of polarised light on the healing of these wounds.



**Figure 7**—A young man with a flame burn to the hand. (A) Appearance 2 days after the injury. (B) The wound was closed after 21 days. (C) Appearance after 19 months. (D) Optimal function of the hand was achieved.

We therefore decided to set up a randomised prospective single-blind study to investigate further the effect of polarised light on the healing of standardised wounds. In 20 patients we compared the healing of pairs of identical donor sites; the wound care protocol was identical for both wounds, except that one donor site was treated with phototherapy and the other site was not. Each patient served as their own control.<sup>19,23</sup>

Because of these convincing results, for over 3 years now we have been treating most superficial and deep second degree wounds in our department with polarised-light therapy. For this study, we selected 22 out of 67 patients with deep dermal burn wounds, which the majority of the surgeons (at least four out of six) in our burn centre would have treated surgically with tangential excision and skin grafting. We wanted to investigate whether the statistically significant results obtained in our donor-site study could be translated to a clinically more relevant study of deep dermal burns.

For objective assessment, four experts in burn care, all heads of specialised burn centres, were asked to evaluate our clinical results. All four surgeons had more than 15 years experience in judging and evaluating the indications for conservative versus surgical treatment of deep dermal burns and in predicting the development of hypertrophic scarring and contractures. These experts would have operated in the majority of the cases presented. Moreover, they all significantly overestimated the healing

period: the actual time to complete wound healing was significantly shorter (22 days versus 41 days). Moreover, in none of these patients would surgery have resulted in an earlier discharge from hospital.

Although no surgical intervention was performed and the panel had expected hypertrophic scarring in the majority of cases (mean: 72%), there was only one case of hypertrophic scarring, in a patient who was not compliant in wearing pressure garments. In the cases where the panel would have recommended surgery, the results after phototherapy were judged to be at least comparable to the expected surgical results in 65.3%. Compared with any other conservative treatment, phototherapy scored at least as well in 97.6% of cases, and better or much better in half the cases.

All our patients were submitted to the usual protocol of customised pressure garments and silicone application, which is standard in our burn centre to prevent hypertrophic scarring. We felt that, after treatment with polarised light, the application of pressure garments and silicone inlays could be started earlier and caused fewer problems with the just-healed skin (less blister formation and epithelial breakdown). We were, however, unable to confirm this clinical impression statistically.

Another major advantage of treating deep dermal burns of the hands with polarised light is that physiotherapy, which is started immediately, can be continued throughout treatment without interruption, in contrast to

operated hands, which always require a period of immobilisation. The promising results of polarised-light therapy in treating deep dermal burns of the hand will be further investigated in a future clinical study. The old dogma of early excision and skin grafting in burns of the hand might have to be reconsidered.

In conclusion, the results of this clinical study demonstrate that polarised-light therapy reduces the need for surgery in the treatment of deep dermal burns. In this group of patients, the use of polarised light accelerated wound healing and allowed very early pressure therapy, thus reducing hypertrophic scarring and contractures. No extension of the hospital stay was required. Because of the better aesthetic and functional results (especially in burns of the hands), polarised-light therapy has become the therapy of choice for deep dermal burns in our University Hospital.

### Acknowledgements

We thank Professor W. Boeckx, Dr R. Peeters, Professor G. Matton, Dr L. Duinslaeger and Dr B. Van den Hof for their collaboration. The authors and the Department of Plastic Surgery at the University Hospital of Gent have no financial interest in the Bioptron Company, who paid for this study.

### References

- Salisbury RE. Thermal burns. In McCarthy JG, ed. *Plastic Surgery*. Philadelphia: W. B. Saunders, 1990: 805.
- Heimbach D, Engrav L, Grube B, Marvin J. Burn depth: a review. *World J Surg* 1992; 16: 10–15.
- Hlava P, Moserová J, Königova R. Validity of clinical assessment of the depth of a thermal injury. *Acta Chir Plast* 1983; 25: 202–8.
- Engrav LH, Heimbach DM, Reus JL, Harnar TJ, Marvin JA. Early excision and grafting vs. nonoperative treatment of burns of indeterminant depth: a randomized prospective study. *J Trauma* 1983; 23: 1001–4.
- Mester E, Spiry T, Szende B, Tota JG. Effect of laser rays on wound healing. *Am J Surg* 1971; 122: 532–5.
- Mester E, Mester AF, Mester A. The biomedical effects of laser application. *Lasers Surg Med* 1985; 5: 31–9.
- Kana JS, Hutschenreiter G, Haina D, Waidelich W. Effect of low-power density laser radiation on healing of open skin wounds in rats. *Arch Surg* 1981; 116: 293–6.
- Lyons RF, Abergel RP, White RA, Dwyer RM, Castet JC, Uitto J. Biostimulation of wound healing in vivo by a helium–neon laser. *Ann Plast Surg* 1987; 18: 47–50.
- Abergel RP, Lyons RF, Castet JC, Dwyer RM, Uitto J. Biostimulation of wound healing by lasers: experimental approaches in animal models and in fibroblast cultures. *J Dermatol Surg Oncol* 1987; 13: 127–33.
- Hunter J, Leonard L, Wilson R, Snider G, Dixon J. Effects of low energy laser on wound healing in a porcine model. *Lasers Surg Med* 1984; 3: 285–90.
- Fenyő M. Theoretical and experimental basis of biostimulation. *Optics Laser Technol* 1984; 16: 209–15.
- Mester E, Nagylucskay S, Waidelich W, et al. Auswirkungen direkter Laserbestrahlung auf menschliche Lymphocyten. *Arch Dermatol Res* 1978; 263: 241–5.
- Karu TI. Photobiological fundamentals of low-power laser therapy. *J Quantum Electronics* 1987; 23: 1703–17.
- Kertész I, Fenyő M, Mester E, Bathory G. Hypothetical physical model for laser biostimulation. *Optics Laser Technol* 1982; 14: 31–2.
- Kubasova T, Fenyő M, Somosy Z, Gázsó L, Kertész I. Investigations on biological effect of polarized light. *Photochem Photobiol* 1988; 48: 505–9.
- Bolton P, Dyson M, Young S. The effect of polarized light on the release of growth factors from the U-937 macrophage-like cell line. *Laser Ther* 1992; 2: 33–42.
- Stäcker AD. Förderung der Wundheilung durch Bestrahlung mit polarisiertem Licht. *Medwelt* 1986; 3–7.
- Stegmann W. Behandlung des Ulcus cruris mit polarisiertem Licht. *Phlebol Proktol* 1985; 14: 96–7.
- Depuydt K, Monstrey S, Hoeksema H. The use of polarized light in the treatment of burn wounds. Abstract. Presented at the 10th Annual EURAPS Meeting, Madrid, Spain, 21 May 1999.
- Cambier DC, Vanderstraeten GG, Mussen MJ, van der Spank JT. Low-power laser and healing of burns: a preliminary assay. *Plast Reconstr Surg* 1996; 97: 555–8.
- Rochkind S, Rouso M, Nissan M, Villarreal M, Barr-Nea L, Rees DG. Systemic effects of low-power laser irradiation on the peripheral and central nervous system, cutaneous wounds, and burns. *Lasers Surg Med* 1989; 9: 174–82.
- Schlager A, Oehler K, Huebner K-U, Schmutz M, Spoetl L. Healing of burns after treatment with 670-nanometer low-power laser light. *Plast Reconstr Surg* 2000; 105: 1635–9.
- Monstrey S, Hoeksema H, Depuydt K, Van Maele G, Van Landuyt K, Blondeel P. The effect of polarized light on wound healing. *Eur J Plast Surg* 2002; 24: 377–82.

### The Authors

**Stan J. Monstrey MD, PhD, FCCP**, Professor and Chief  
**H. Hoeksema**  
**H. Saelens**  
**K. Depuydt**  
**Moustapha Hamdi**  
**Koenraad Van Landuyt MD, FCCP**, Associate Professor  
**Phillip N. Blondeel**

Department of Plastic Surgery, University Hospital Gent, De Pintelaan 185, B-9000 Gent, Belgium.

Correspondence to Professor Stan J. Monstrey, MD.

Paper received 13 February 2001.

Accepted 22 April 2002, after revision.